

# The Clinical Utility Of CD10 Immunohistochemical Staining In The Diagnosis Of Endometriosis.

Roger McMaster-Fay, Robert Osborn, Edward Chandraratnam

## INTRODUCTION

Published series from respectable units (Mayo Clinic<sup>1</sup>; NIH, Bethesda, Maryland<sup>2</sup>; M.Reese, Chicago<sup>3</sup>) have found that over one third (43%<sup>1</sup>; 33%<sup>2</sup>; 36%<sup>3</sup>) of surgically obtained biopsies of endometriosis are histologically negative on H&E staining, with higher rates of negativity with lower graded disease:

- 60% in Stage I (Minimal) disease;
- 30% in Stage II-III (Mild-Moderate) disease;
- 0% in Stage IV (Severe) disease<sup>1</sup>.

Groisman and Meir (2003)<sup>4</sup> retrospectively studied 20 cases of histologically equivocal endometriosis ('suspicious of', 'suggestive of' or 'compatible with') and found that 85% stained positive for CD10, confirming the diagnosis.

Potlog-Nahari et al. (2004)<sup>5</sup> using CD10 immunohistochemical staining in 31 women with chronic pelvic pain, found that almost doubled (X1.8: 9->16) their diagnosis of Stage I endometriosis.

## PATIENTS & METHODS

A prospective study, from March 2007 to the end of the year, using immunohistochemical staining for the endometrial stromal antigen CD10, was performed on histologically (H&E stained) negative laparoscopic biopsies of lesions thought, surgically, to be endometriosis.

Over the ten month period 23 patients had laparoscopic directed biopsies of pelvic peritoneal lesions considered clinically to be endometriosis but were histologically (H&E) negative. All specimens were then stained immunohistochemically for the antigen CD10.

Because of initial promising results, 8 patients had samples examined retrospectively from the previous 2 years. Five of these patients were also in the prospective study (i.e. having a second laparoscopy).

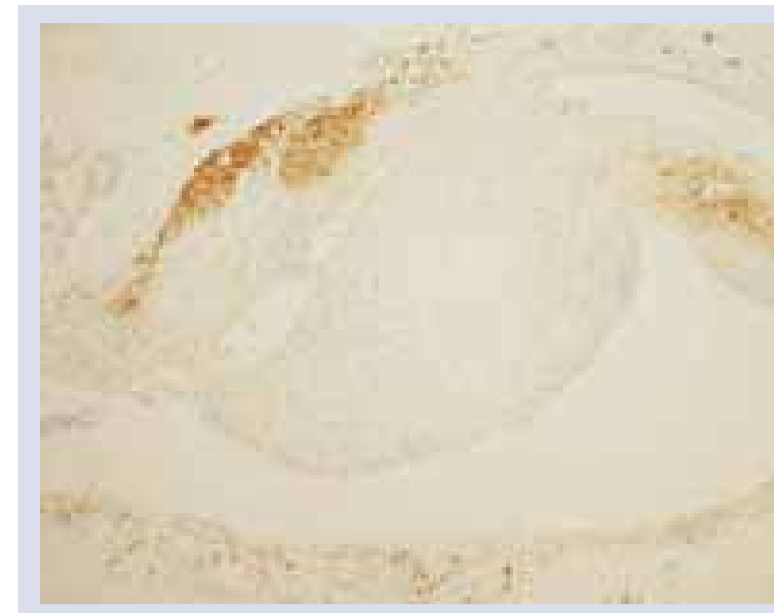
## RESULTS

In the prospective study there were 60 patients, 37 (62%) showed frank endometriosis in an original biopsy and 23 were uncertain or negative (38%).

Combining both studies, there were 31 histologically (H&E) negative patients, 23 (74%) were found to have CD10 positive immunohistochemical staining of endometrial stromal cells (n=20) (Illustration 1) or granulomas (n=3). The remaining eight patients were negative for CD10, although one of these patients was a retrospective patient who was subsequently positive in the prospective study

### REFERENCES:

1. Walter AJ, et al. Am J Obstet Gynecol 2001;184:1407-13.
2. Stratton P, et al. Fertility & Sterility 2003;79:1078-85.
3. Chatman DL, Zbella EA. J Reprod Med 1987;31:855-7.
4. Groisman GM, Meir A. Arch Pathol Lab Med 2003;127:1003-6.
5. Potlog-Nahari C, Stratton P, et al. Fertility & Sterility 2004;82:86-92.
6. Brosens IA. Modern Approaches to Endometriosis. (Kulwer Academic, Dordrecht)1991;21-32.

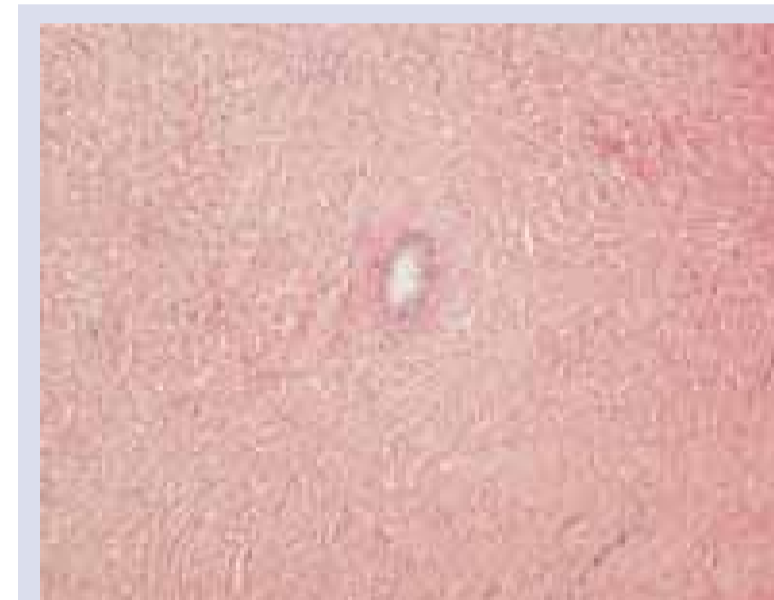

**Illustration 1**

*Positive CD 10 Staining of stroma in previously reported as negative on H&E (x 100)*

There were a number of cases during the study period histologically (H&E) diagnosed as having endosalpingiosis and all were CD10 negative.

There was one ovary removed with a chronic chocolate cyst (endometrioma; endometriotic cyst). Macroscopically it was a classic endometriotic cyst but on histology there was no epithelial lining. CD10 staining was positive in another focus in the ovary confirming endometriosis (Illustrations 2 & 3)



**Illustration 2**

*H&E stained section showing glandular focus which cannot be diagnosed as endometriosis (x 100)*



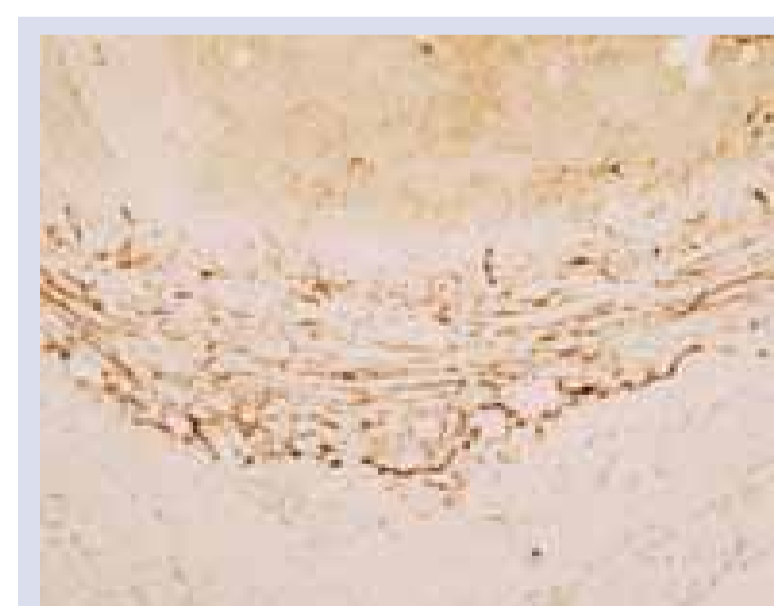**Illustration 3**

*Positive CD 10 Staining of stroma in ovarian endometriotic (x 100)*

## DISCUSSION & CONCLUSIONS

As with the two previously published series<sup>4 & 5</sup>, we were able to dramatically lower the false negative rate of the histology of peritoneal implants of endometriosis using CD10 immunohistochemistry.

The positive staining of granulomas, usually thought to just indicate previous diathermy injury, may be due to the presence of the CD10 antigen coming from endometrial stromal cells and therefore indicative of endometriosis. (Illustration 4)



**Illustration 4**

*Positive CD 10 Staining of stroma adjacent to diathermy injury previously reported as negative on H&E (x 100)*

Endosalpingiosis is histologically glands with no stromal cells. In this study CD10 immunohistochemistry confirmed this diagnosis in all cases.

Up to one third of 'chocolate cysts' no specific pathology can be found (Brosens 1991<sup>6</sup>) i.e. there is no lining epithelium and no obvious stromal cells. From our experience CD10 immunohistochemistry is likely to support the diagnosis in at least some cases.